

Patient Report

Patient ID:

SIA 002

Patient Name:

No Patient Name

Patient Address:

No Patient Address

Specialist:

Julian Roberts

Clinic Name:

Mole Stop

Clinic Address:

119 Sunnynook Road

North Shore City
Auckland

New Zealand

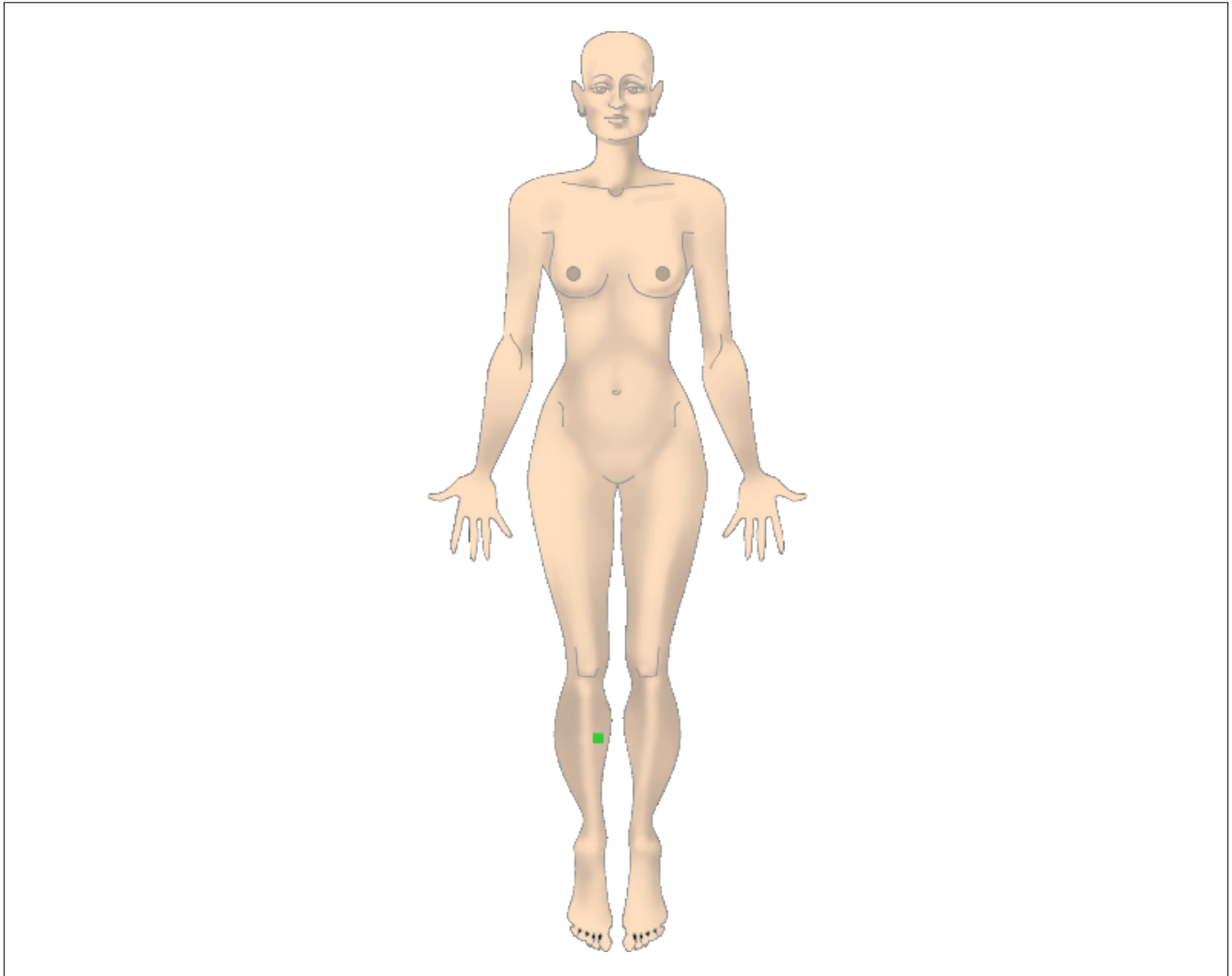
Date: 7/01/2006

Patient Report

Patient ID:
SIA 002
Patient Name:
No Patient Name

Confidential

Lesion Location



Lesion ID:	77
Lesion Status:	High
Name:	SIAGraph 11/12/05
Date:	1/12/2005
Notes:	

There is migration of melanocytes into the dermis (View 3) but no significant blood displacement or collagen fibrosis.
In view of past history of malignant melanoma recommend excision biopsy

Patient Report

Patient ID:
SIA 002
Patient Name:
No Patient Name

Confidential

SIAGraph Contact Image

Lesion ID: 77
Lesion Status: High
Name: SIAGraph 11/12/05
Date: 1/12/2005

